

Breast Shape Analysis With Curvature Estimates and Principal Component Analysis for Cosmetic and Reconstructive Breast Surgery

Aesthetic Surgery Journal
2019, Vol 39(2) 164–173
© 2018 The American Society for
Aesthetic Plastic Surgery, Inc.
Reprints and permission:
journals.permissions@oup.com
DOI: 10.1093/asj/sjy070
www.aestheticsurgeryjournal.com

OXFORD
UNIVERSITY PRESS

Giuseppe Catanuto, MD, PhD; Wafa Taher, MRCS, MS;
Nicola Rocco, MD, PhD; Francesca Catalano, MD, PhD;
Dario Allegra, MS, PhD; Filippo Luigi Maria Milotta, MS, PhD;
Filippo Stanco, MS, PhD; Giovanni Gallo, MS, PhD;
Maurizio Bruno Nava, MD

Abstract

Background: Breast shape is defined utilizing mainly qualitative assessment (full, flat, ptotic) or estimates, such as volume or distances between reference points, that cannot describe it reliably.

Objectives: The authors quantitatively described breast shape with two parameters derived from a statistical methodology denominated by principal component analysis (PCA).

Methods: The authors created a heterogeneous dataset of breast shapes acquired with a commercial infrared 3-dimensional scanner on which PCA was performed. The authors plotted on a Cartesian plane the two highest values of PCA for each breast (principal components 1 and 2). Testing of the methodology on a preoperative and posttreatment surgical case and test-retest was performed by two operators.

Results: The first two principal components derived from PCA characterize the shape of the breast included in the dataset. The test-retest demonstrated that different operators obtain very similar values of PCA. The system is also able to identify major changes in the preoperative and posttreatment stages of a two-stage reconstruction. Even minor changes were correctly detected by the system.

Conclusions: This methodology can reliably describe the shape of a breast. An expert operator and a newly trained operator can reach similar results in a test/re-testing validation. Once developed and after further validation, this methodology could be employed as a good tool for outcome evaluation, auditing, and benchmarking.

Level of Evidence: 4

Editorial Decision date: March 5, 2018; online publish-ahead-of-print March 20, 2018.



Dr Catanuto is Dirigente Medico at U.O.C. Multidisciplinare di Senologia, Azienda Ospedaliera Cannizzaro Catania, Catania, Italy; and Group for Reconstructive and Therapeutic Advancements, Milano-Napoli-Catania, Italy. Ms Taher is Fellow of the International Fellowship Mr G. Querci della Rovere and Locum Consultant, Oxford University Hospital NHS Foundation Trust, Oxford, UK. Dr Rocco is a Consultant Oncoplastic breast Surgeon at Department of Clinical Medicine and Surgery, University of Naples “Federico II”, Naples, Italy. Dr Catalano is Direttore U.O.C. Multidisciplinare di Senologia, Azienda Ospedaliera Cannizzaro Catania, Catania, Italy. Drs Allegra and Milotta are Research Consultants, Dr Gallo is a Full Professor,

and Dr Stanco is an Associate Professor, Dipartimento di Matematica e Informatica, Università degli Studi di Catania, Catania, Italy. Dr Nava is a Consultant, Group for Reconstructive and Therapeutic Advancements, Milano-Napoli-Catania, Italy.

Corresponding Author:

Dr Filippo Luigi Maria Milotta, Viale Andrea Doria 6, University of Catania, Department of Mathematics and Computer Science, Catania 95125, Italy.

E-mail: milotta@dmf.unict.it; Twitter: @Greta.Oncoplast

Oncological or cosmetic surgery transforms the shape of the breast; quantification of cosmetic results is partially subjective and might be biased according to personal beliefs, or social or ethnic considerations. Shape is a geometric property of an object; it does not entirely describe cosmetic results but could be considered a main part of the outcome evaluation. In geometrical terms, the breast can be regarded as a curved surface lying on the chest wall, thus curvature could be a relevant estimate to characterize it.^{1,2} Currently, breast shape is defined utilizing mainly a subjective qualitative assessment (full, flat, ptotic) which is poorly reproducible or utilizing estimates, such as volume or distances between reference points, that cannot describe it reliably. We propose a methodology based on surface curvature that can quantify breast shape in a simple way utilizing two numerical parameters.

METHODS

Population

After review of the study protocol and formal approval by the internal ethics committee of the Associazione Santantonese per la Lotta ai Tumori (ASLT), a population of 52 female volunteers was identified during clinical consultations for a total number of 71 breasts examined from January 2016 to December 2016. We included healthy women irrespective of the size and shape of their breasts, including those with tuberous breasts, severely hypotrophic glands, or gigantomastia, to have a dataset completely representative of shape variability. We excluded women younger than 18 years of age, with cognitive impairment, or those affected by Poland syndrome. Some volunteers consented to scan only one side, because this was allowed by the study protocol. The average age of the sample was 41 years (range, 19–69 years). Bra cup size was self-reported by the patients, and the degree of ptosis according to Regnault³ was recorded (Table 1); the median BMI was 24 kg/m² (range, 20–40 kg/m²). This dataset was employed to build the mathematical model utilized to reduce the number of parameters characterizing the breast shape. In addition to the sample of 52 female volunteers, a patient affected by breast cancer who underwent mastectomy and reconstruction with a two-stage procedure was involved in the validation phase of this study. This woman had very small breasts preoperatively; she underwent a left mastectomy and a two-stage reconstruction with a larger tissue expander to allow a contralateral augmentation at the second stage. After the reconstructive process, the resulting outcome was slightly asymmetrical. This case was included to assess the ability of the system to detect minor changes preoperatively and postoperatively. It is also descriptive of modifications induced by augmentation mammoplasties performed as a cosmetic procedure. Two

Table 1. Dataset Population

	Ptosis				Volume (bra cup size)					
Degree	1	2	3	4	AA	A	B	C	D	E
Occurrences	14	10	30	17	5	22	25	13	4	2

different operators (G.C. and W.F.) were tested utilizing this specific case to assess the reproducibility of the estimates produced by our system.

Device

We employed the Structure Sensor (Occipital, San Francisco CA, USA), a 3-dimensional (3D) scanner with structured infrared light technology. The Structure Sensor can acquire information about the depth of thousands of points at the same time. The depth is defined as the distance of the scanned object from the sensor itself. This handheld scanner can acquire information from a distance up to 12 meters (recommended range is 0.4-3.5 m). Its maximum accuracy is 0.5 mm, but its accuracy declines when it is utilized to scan larger areas. These specifications make this device easily employable by doctors in small rooms. The models are digitized through a calibration that preserves the real size of the breasts. The sensor itself is not able to acquire the color of the skin. However, it is possible to plug it into an iPad and utilize the tablet camera for this purpose (Figure 1). The overall cost of these devices is approximately \$1,000.

Acquisition Methodology

A 3D scan of the chest of the female volunteers was performed in a standing position with hands behind and above the head. The scan was acquired by operators moving the infrared Structure Sensor camera clipped onto the iPad around the female volunteer without marking or touching her. The average acquisition time of the scanning was 1 minute.

Post-Processing and Principal Component Analysis

After the scan, 3D meshes derived from the acquisition were marked with four standard reference points, according to relevant anatomic landmarks (sternal notch, anterior axillary line from its origin at the lateral insertion of the pectoralis major) or reference points identified on the mesh (conjunction between the anterior axillary line and the midline with a plane tangential to the lowest point of the breast). The four reference points generated identified a so-called “region of interest (ROI),” and all



Figure 1. iPad with infrared camera.

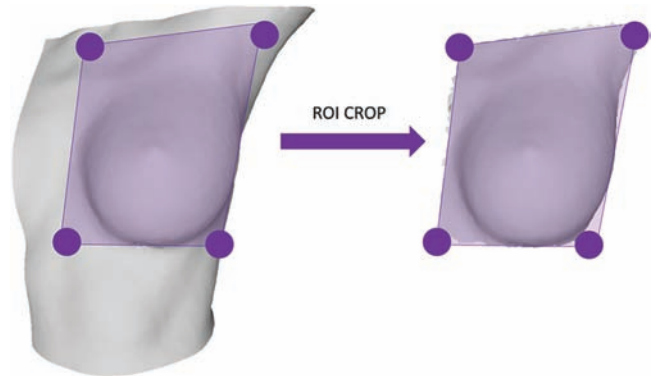


Figure 2. Reference points on the mesh and region of interest (ROI).




Figure 3. The pipeline of the proposed method. Note that PCA is applied on 64-dimensional breast descriptors represented in the pipeline through a sample normalized histogram. This kind of histogram has 64 bins on normalized percentage values. Then, the built mathematical model is utilized to extract two parameters from each of the 3D meshes.

analyses were performed only on this sectioned surface (Figure 2).

Each acquired mesh consists of a set of points in the 3D space. To enable a clinically acceptable characterization, we needed to reduce it into a simple set of parameters. Therefore, the geometrical orientation of each point of the mesh was exploited to address this problem. The first step of this process required a transformation of each surface into the same coordinated system. Because the scale is the same across all meshes, we needed to transform origin coordinates and orientation. The origin of each mesh was set into its own barycenter (average point), and we chose as a standard orientation the one along the average direction of the whole point set (Figure 3). To find the rotation parameters mathematically, we utilized the Rodrigues' rotation formula.⁴

After meshes were correctly transformed, the orientation space was clustered. We identified 64 different possible orientations in the 3D space (this number arises from the

maximum possible combinations of a space quantization with four values along X, four values along Y, and four values along Z). Then, we estimated for each mesh the occurrence of each possible orientation (Figure 4). This process allowed every single 3D mesh to be represented as a 64-bin histogram. However, a representation based on 64 values to describe a breast shape is not understandable by a human reader.

Hence, to further reduce the number of parameters characterizing the breast shape, we employed a popular mathematical procedure called "principal component analysis (PCA)." If PCA is performed on data in an N-dimensional space, it computes the $N \times N$ correlation matrix and then its eigenvalues and eigenvectors. The largest eigenvalues are related to the principal components, whereas the related eigenvectors are utilized to perform the space transformation. In our study, we utilized PCA to compute the two most significant components in the 64-dimensional space. This allowed us to describe the breast shape with

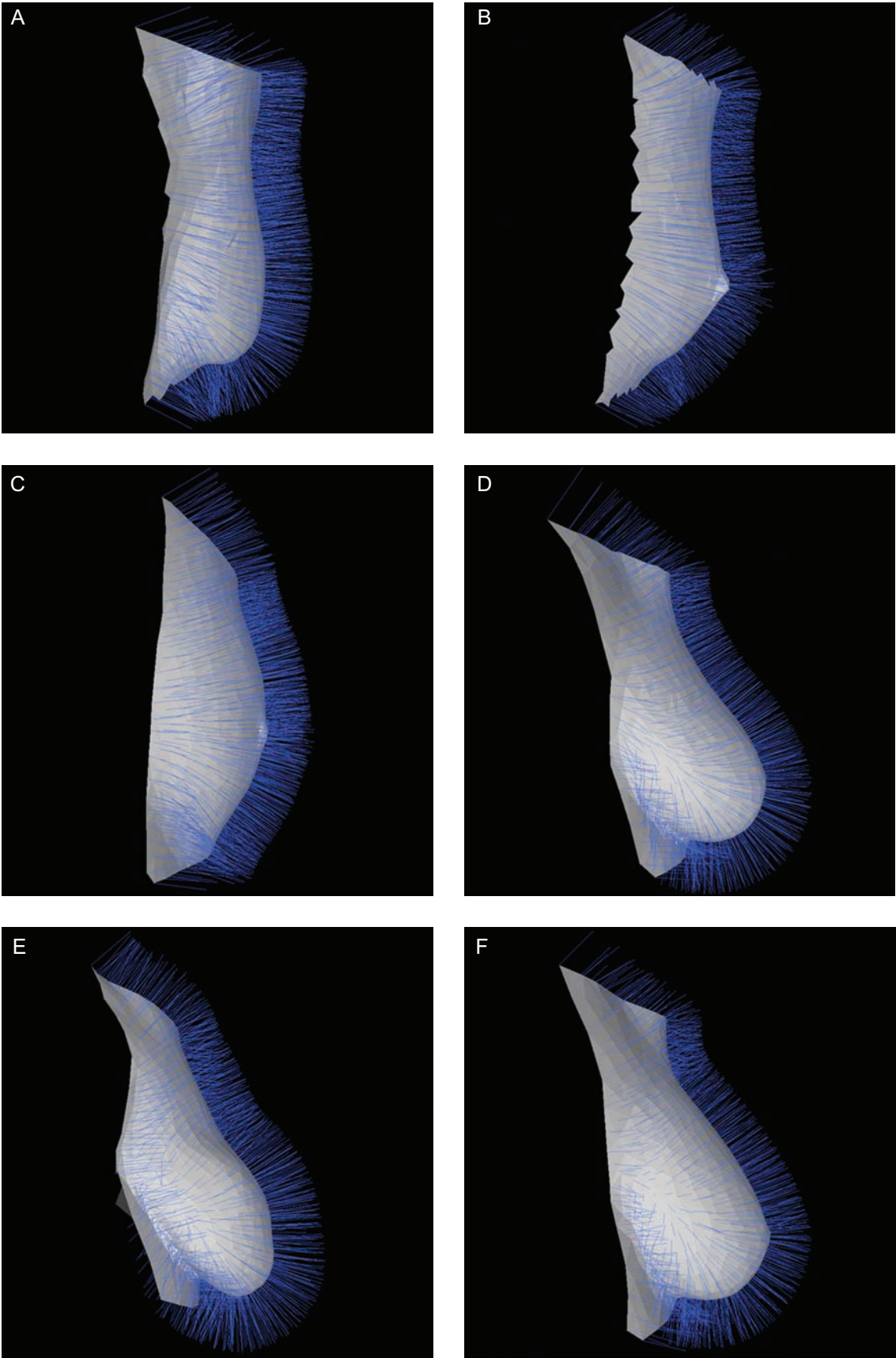


Figure 4. Example models showing (A, B, C) low and (D, E, F) and high curvature variability. Representative (A) 69-, (B) 30-, (C) 29-, (D) 56-, (E) 69-, and (F) 33-year-old female patients are shown.

just two parameters and visualized it in a 2-dimensional (2D) Cartesian coordinate system.

Validation (Inter- and Intra-Operator Testing)

To assess the clinical reproducibility of this protocol, we invited two operators (expert and junior) to perform multiple scans on the same female volunteer already treated with mastectomy and breast reconstruction in two stages. Each operator acquired 26 scans (13 of the left breast and 13 of the right breast) and performed the identification of the ROI on the 3D mesh in the postprocessing phase. We examined the breast area bilaterally at the end of tissue expansion and 6 months after the second reconstructive stage.

RESULTS

The PCA analysis of the dataset of asymptomatic patients identified two principal components, denominated principal component 1 (PCA1) and principal component 2 (PCA2); these were associated with a variance retained of $48:04 + 29:35 = 77:9\%$ (Figure 5). A plot was generated utilizing the two principal components (PCA1 and PCA2) as coordinates of a single breast on a Cartesian plane. We observed that different shapes were associated with specific values of PCA1 and PCA2 and that a rough correlation existed between these values and some qualities of the breast (ie, breast ptosis and volume). Analyzing three different shapes (A: large and ptotic; B: medium and ptotic; C: small, no ptosis), we observed the following (Figure 6):

- A was located in the left region of the plane (A: PCA1 = -0.17; PCA2 = -0.04)
- B was in the central area (B: PCA1 = 0; PCA2 = -0.02)
- C was in the right area (C: PCA1 = 0.11; PCA2 = 0.01)

The PCA analysis was conducted employing the 71 models acquired from the 52 female volunteers (Table 1). Then, we performed a test case employing a total of 68 additional models, as defined in Section 2.1. The test-retest, performed by a senior operator and a junior operator on the same patient during tissue expansion, demonstrated that scans from the same breast can be reproduced reliably, and that very different shapes retain very different values of PCA1 and PCA2 when plotted (Figures 7A and 7C). For the left breast (from the point of view of the volunteer), the mean PCA values were PCA1 = 0.12 and PCA2 = 0.0198, with Standard Deviation SD = (0.0127, 0.0262), whereas for the right breast, the mean PCA values were PCA1 = 0.0098 and PCA2 = 0.0281, with SD = (0.0138, 0.0139) (Table 2). Significantly, the standard deviation demonstrated that the values of PCA could be more dispersed when anatomic landmarks of the breast

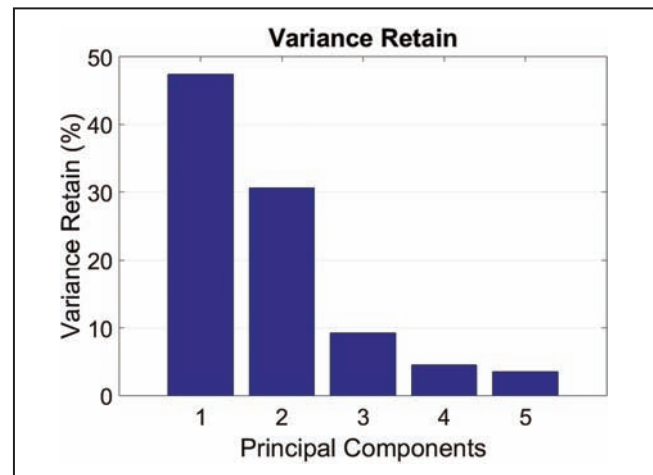


Figure 5. PCA variance retain values of the first five principal components.

boundaries are not easily identifiable, as on the left side of this patient (red markers on the right side).

After the second reconstructive stage, the two breasts still retained different shapes. Once again, the system, in the hands of two different operators, identified morphological changes induced by surgical operations. (Mean post-treatment values LEFT: PCA1 = 0.0124; PCA2 = 0.0352; SD = (0.0181, 0.0353). Mean posttreatment values RIGHT: PCA1 = 0.0273; PCA2 = 0.0843; SD = (0.0258, 0.0129).) Minor residual posttreatment difference (Figures 7B, 7C, and 8) were also characterized.

DISCUSSION

A recent systematic review by Maass⁵ assessed the possible scales for evaluation of cosmetic results currently available in the literature utilizing a modified version of the Scientific Advisory Committee's Medical Outcomes Trust (MOT). A relevant number of the scales included an assessment of breast morphology. This was performed utilizing linear measurements with flexible tapes and calipers, or utilizing digital photographs in a setting still subject to bias due to lighting and position, or utilizing thermoplastic casts to assess the breast volume in a reliable way.⁶⁻⁹

In one of the studies included in this review, for instance, Gahm et al⁹ reported on symmetry evaluation utilizing distances between anatomic landmarks on the two sides of the chest wall. However, although different operators could easily reproduce the linear measurements, they could not, in our opinion, reliably represent the shape of a curved surface. Thermoplastic casts were utilized to estimate breast volume. This technique is time-consuming and unpleasant for patients, but it is also completely pointless in terms of shape evaluation because different shapes may retain identical volumes.

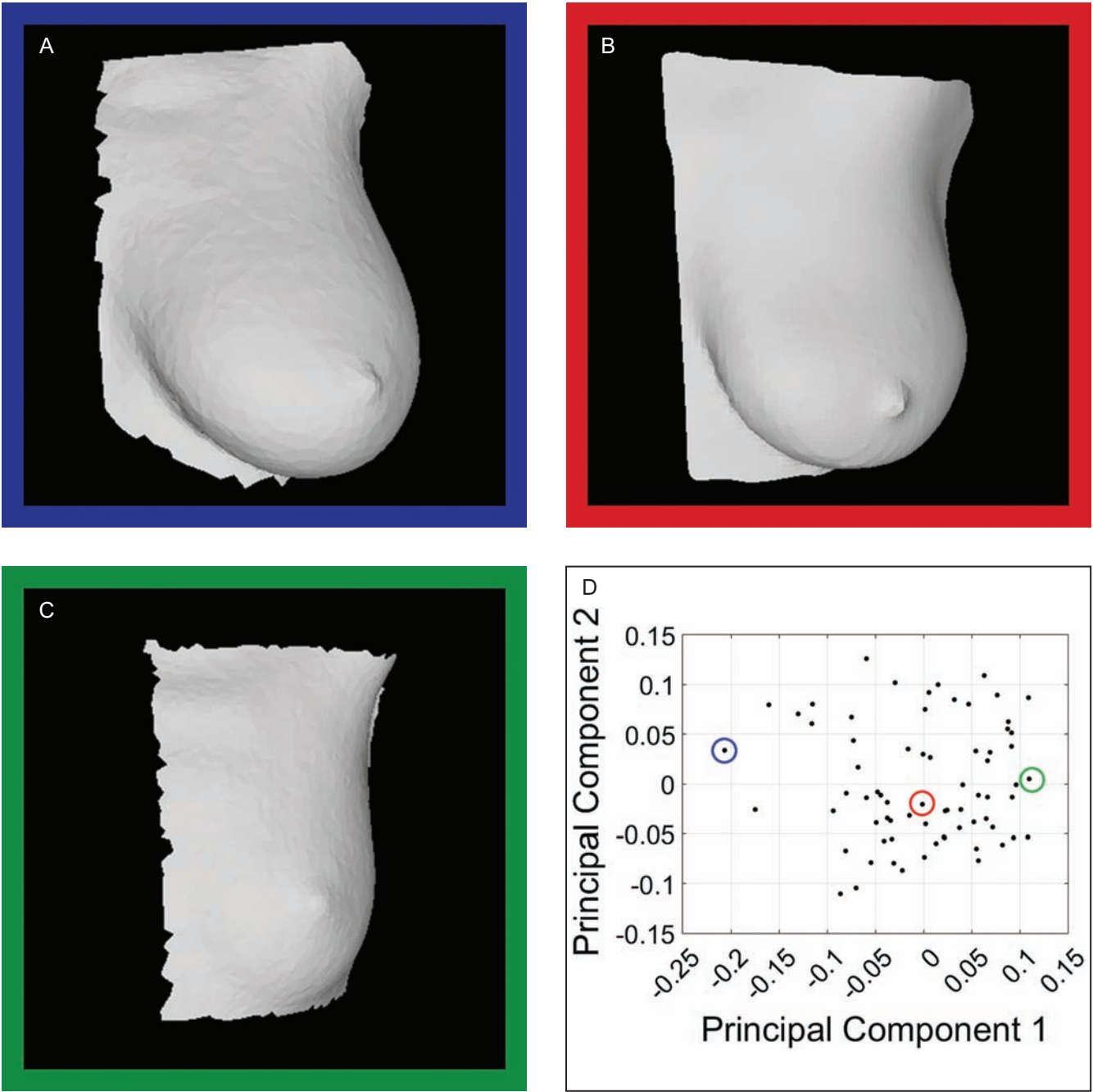


Figure 6. (A-D) A plot of PCA1 and PCA2 values identifying each breast, as computed on dataset and Table 1. Different values can be roughly associated with different volumes and degrees of ptosis, as defined by Regnault. On the left area, we can have large and ptotic breasts (model A is highlighted in blue), in the central part of the plane medium-size and moderately or nonptotic breasts (model B is highlighted in red), and on the right area small and non-ptotic breasts (model C is highlighted in green). We show the meshes of selected models together with their normals: the different distribution of orientations between them is clearly visible. Representative (A) 33-, (B) 40-, and (C) 36-year-old female patients are shown.

In the large majority of the studies reported by Maass,⁵ the evaluation of breast shape seems either complex, poorly reproducible, or based on unappropriated measurements, despite several efforts. Two recent protocols proposing a

tool for the objective evaluation of cosmetic outcome were specifically designed to eliminate the subjective component in the assessment of cosmetic results. The first one, from Fitzal et al,¹⁰ is a software tool called BAT (breast

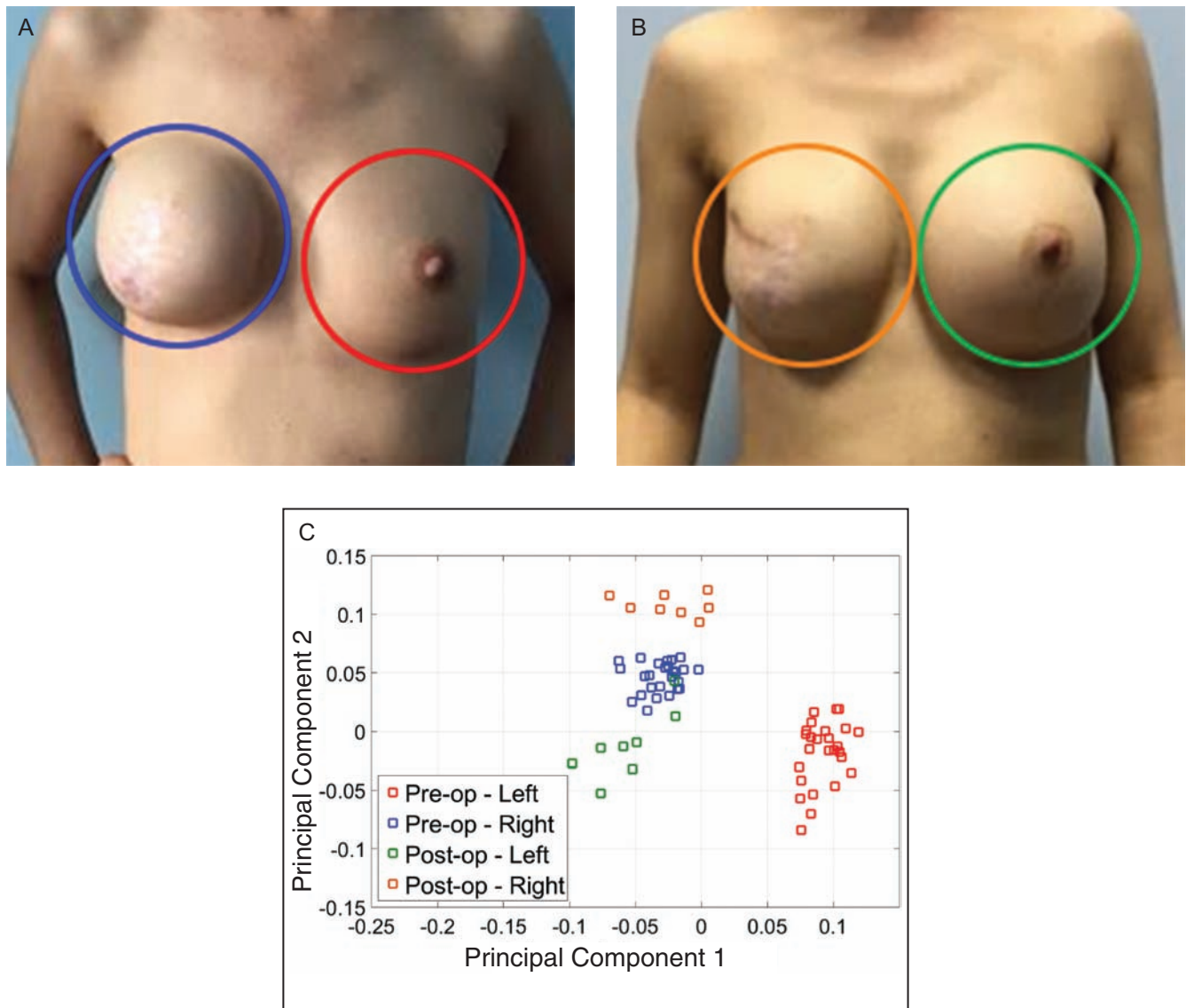


Figure 7. (A-C) An additional 68 preoperative and postoperative scans by different operators on the two sides before and after right mastectomy and tissue expansion (of the same 38-year-old representative female patient). Completely different shapes are in very different areas of the plane. The left breast (with relation to the point of view of the volunteer) is less precisely identified. This can be due to uncertainties in the identification of anatomic reference points. Compared to preoperative scans, postoperative scans have first principal component values more similar to each others. The right breast (with relation to the point of view of the volunteer) is completely transformed by the augmentation and retains completely different values, when compared with the preoperative view. The change to a permanent implant has modified even the shape of the left breast. The system can identify slightly asymmetrical results.

analyzing tool) that can calculate a breast symmetry index (BSI) utilizing distances between relevant landmarks of both breasts on 2D digital photography (front and side views). A team of healthcare specialists was invited to assess the results subjectively utilizing a Harris scale for subjective outcome. This was correlated with the BSI to demonstrate an excellent inter-observer reproducibility (Pearson correlation $r = 0.9$; $P < .05$), and the BSI was significantly differentiated between good and bad cosmesis. The authors have recently improved this system, and

further developments are forthcoming.¹¹ Even the BCCT.core^{12,13} is based on 2D photographs (frontal views); however, differently from the BAT, it also includes the evaluation of scars and skin color. This system classifies results in four classes that were validated assessing the consensus of a panel of experts.¹⁴ The BCCT.core was tested against the BAT demonstrating its superiority when performed on high-resolution images, and this could probably be due to the ability of variations in the skin.¹⁵ The BCCT.core is therefore considered the most advanced tool, and it was

Table 2. Preoperative and Postoperative PCA Mean and Standard Deviation Values of the 68 Additional Meshes

	Preoperative		Postoperative	
	Left	Right	Left	Right
Mean	(0.0924, -0.0183)	(-0.0307, 0.0462)	(-0.0563, -0.0116)	(-0.0236, 0.1080)
Standard deviation	(0.1320, 0.0272)	(0.0150, 0.0127)	(0.0274, 0.0291)	(0.0276, 0.0091)

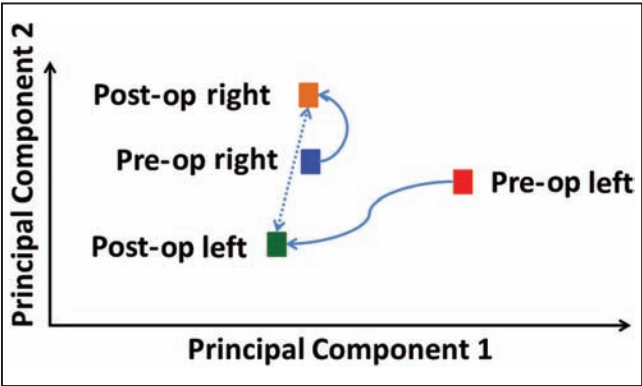


Figure 8. Simplified demonstration of results shown in Figure 7C. The representative patient is this 38-year-old woman.

utilized in a recent trial for the evaluation of cosmetic results.^{16,17} Both systems are based on bi-dimensional assessment of breast shape, although this is clearly 3D. Thus, the 2D evaluation may miss a substantial amount of information.

Digital Three-Dimensional Assessment of Breast Shape and Our Experience

Several devices can be utilized to produce 3D pictures of an object. Some of these were developed for a specific clinical need. Despite a relatively high level of technological development, all these systems are still far from being utilized in everyday clinical practice. A standard set of reliable descriptors of shape is lacking. Some studies, for instance, attempted to assess the breast volume. This can be done by optical systems in a reliable way, although the posterior wall (chest) can only be estimated utilizing MRI or CT scans. Early validation of volume assessment and linear measurement was provided by Losken.¹⁸ A study by Tepper¹⁹ provided visual depictions of volume displacement after surgery for glandular reduction with false color maps. This was based on the calculation of distances between the breast surface and the chest wall. However, the chest wall cannot be detected by surface scanners like those employed in this study, and this may affect the clinical strength of the proposed methodology. Moreover, the number of estimates proposed by the author is very high, and it may create a complex amount of data that are poorly

manageable when performing clinical audits. Several more attempts to characterize the shape of the breast with different kinds of 3D scanners are available in the literature.^{20–24} Most of these are still based on volume rather than shape calculation, and volume is clearly not representative of shape; indeed, surgical procedures on the breast transform not only the volume but also the shape. For instance, after a breast augmentation either with round or anatomic implants, you can have not only two different shapes but also the same volume. None of them have generated a standard set of measurements, and the real usefulness of 3D systems remains questionable, especially if we consider higher costs and more complex management.²⁵

Breast Shape Analysis in Our Experience: Curvature Estimates and Principal Component Analysis for Cosmetic and Reconstructive Surgery

We demonstrated in our previous experience that curvature could be a good descriptor of breast shape.²⁶ We can associate curvature with common qualitative estimates such as ptosis or volume (a very curved breast is usually large and ptotic, whereas a flat one can be very small and without ptosis). However, although curvature is a local property that can be estimated in a defined region of the breast, a single value cannot describe the entire surface.

We utilized PCA in another previous study based on MRI scans, and we found that this methodology could be a good tool for a simple parametric representation of breast shape. Although MRI produced a reliable description of breast shape, this procedure is time-consuming and not cost-effective.²⁵

In the present study, we merged these experiences, creating a simple and affordable methodology, to obtain two descriptive simple parameters that can be associated with the shape of a breast.

We identified a heterogeneous sample of 41 female volunteers who were scanned utilizing a commercial device connected to an iPad. The acquisition was fast (approximately 1 minute) and could be performed in an office setting. In the post-processing phase, we identified 64 possible orientations in the 3D space (4 values along x, y, and z) and we estimated the occurrence of each possible orientation in every single breast mesh. This orientation in space could

be roughly associated with local curvature of the breast; for instance, the surface of a small and flat breast may be oriented almost entirely in a horizontal direction, whereas a large and ptotic breast may be very curved, and; therefore, its surface can be oriented in many directions.

To reduce the complexity of this system, we utilized the PCA to obtain just two parameters, representative of every single breast shape in a dataset of 71 models, acquired from a population of 52 female volunteers (Section 2.1). The results demonstrated that there is an intuitive association between morphological qualities of the breast (mainly ptosis and volume) and PCA values when plotted on a Cartesian plane. Breasts with different shapes were in different areas of the plane and retained different values of PCA1 and PCA2 (Figure 6).

To confirm this hypothesis, we performed a test-retest procedure with an experienced operator and an untrained one, on 68 additional models from a single volunteer. Results confirmed that most of the time PCA values of a single breast tested at different times by different operators were very similar. A slightly higher variability was seen when the test was performed on very small breasts with boundaries that were rather uncertain. To confirm the capability of this system of describing breast shapes, we tested it in a preoperative/postoperative setting. We tested the system after the second stage of a two-stage reconstruction in a patient who received a contralateral breast augmentation, and we demonstrated the sensibility of the system in describing morphological changes induced by surgery. The flat breast was deeply modified by the augmentation and retained completely different posttreatment values of PCA. These were very similar but not identical to those of the contralateral one, providing evidence of a partial failure of the reconstructive surgery. All these clinical conditions are clearly visible in standard 2D photographs, but quantifications are not possible.

The results of this test on a patient affected by breast cancer could be easily generalized to cosmetic patients. In fact, the contralateral breast augmentation was performed utilizing a standard dual-plane technique. The estimates provided by the system are clearly indicating a significant change in shape that is likely to be in every other case of cosmetic augmentation.

Similar conclusions can be addressed regarding breast reductions. In the database of healthy patients who did not receive any kind of surgery in the past, small breasts can be regarded as the final shape of cosmetic reductions. The PCA values of small breasts are completely different from those of preoperative ones (large breasts in the current database).

The proposed methodology seems to be able to describe the shape of a breast utilizing just two numbers (ie, the first two values of PCA). This system could be integrated into validated scales for cosmetic assessment providing

a simple and objective assessment of the shape. It could replace linear measurements, volume measurements, or curvature maps. The tool is expected to allow auditing and benchmarking, and to describe any alteration of shape induced by surgery, capsular contracture, or any other physiological change (ie, puberty, pregnancy, menopause, malformations) with clear improvements in the quality of the surgical practice. An objective quantitative classification of morphology will be certainly possible.

This system could also be useful for research purposes. Shape analysis with PCA could be one of the outcome measurements in trials on new implants (for instance, anatomic vs. round) or new surgical techniques (ie, epi-pectoral breast reconstructions vs submuscular), because it would be able to track changes induced by surgery in the short term and over time. Joint measurements of morphology and patient-reported outcomes (PROMs) may provide information regarding combined objective and subjective satisfaction with the breast according to shape.

Furthermore, complex and expensive acquisition systems could be ruled out by this simple commercial device, connected to an infrared camera that can perform fast and noninvasive scans. Once a proper definition of shape is provided, old qualitative or semi-quantitative estimates will be pointless. The surgeon will not care about volumes, and data regarding the final values of shape will be part of the decision-making process. Utilizing this device, the surgeon will be able to provide precise estimates of outcome either for the technique he is going to perform or for his capability of reaching them. The results of PCA analysis could also be useful in a possible certification process in which surgeons could demonstrate their outcomes in terms of final morphology and associate them with patient satisfaction.

The system has some limitations: it is not able to acquire the elastic deformation of the breast with trunk movements (static view) the postprocessing is not entirely automatic, and a more precise identification of the ROI (region of interest) could be provided.

CONCLUSIONS

The assessment of breast shape with PCA may become the new gold standard in the preoperative and postoperative evaluation of surgical results. After further development, this system will generate quantitative estimates with classifications of morph types, data exchange, and comparisons among different series or during the follow-up.

Disclosures

The authors declared no potential conflicts of interest with respect to the research, authorship, and publication of this article.

Funding

The authors received no financial support for the research, authorship, and publication of this article.

Acknowledgments

The authors would like to acknowledge Associazione Santantonese per la Lotta ai Tumori (ASLT) for providing logistic support; Ms. Rosamaria Patanè and Concetta Fichera, PsyD, for valuable cooperation in the recruitment of volunteers; and Prof Robert Coghlan for language editing and reviewing. We also thank G.R.E.T.A. (Group for Reconstructive and Therapeutic Advancements) for study design and scientific support.

REFERENCES

1. Gamelin FX, Baquet G, Berthoin S, et al. Effect of high intensity intermittent training on heart rate variability in prepubescent children. *Eur J Appl Physiol*. 2009;105(5):731-738.
2. Lee J, Chen S, Reece GP, Crosby MA, Beahm EK, Markey MK. A novel quantitative measure of breast curvature based on catenary. *IEEE Trans Biomed Eng*. 2012;59(4):1115-1124.
3. Regnault P. Breast ptosis. Definition and treatment. *Clin Plast Surg*. 1976;3(2):193-203.
4. Belongie S. Rodrigues' rotation formula. Wolfram MathWorld website. <http://mathworld.wolfram.com/RodriguesRotationFormula.html>. Accessed July 29, 2017.
5. Maass SW, Bagher S, Hofer SO, Baxter NN, Zhong T. Systematic review: aesthetic assessment of breast reconstruction outcomes by healthcare professionals. *Ann Surg Oncol*. 2015;22(13):4305-4316.
6. Thomson HJ, Potter S, Greenwood RJ, et al. A prospective longitudinal study of cosmetic outcome in immediate latissimus dorsi breast reconstruction and the influence of radiotherapy. *Ann Surg Oncol*. 2008;15(4):1081-1091.
7. Visser NJ, Damen TH, Timman R, Hofer SO, Mureau MA. Surgical results, aesthetic outcome, and patient satisfaction after microsurgical autologous breast reconstruction following failed implant reconstruction. *Plast Reconstr Surg*. 2010;126(1):26-36.
8. Eriksen C, Lindgren EN, Frisell J, Stark B. A prospective randomized study comparing two different expander approaches in implant-based breast reconstruction: one stage versus two stages. *Plast Reconstr Surg*. 2012;130(2):254e-264e.
9. Gahm J, Edsander-Nord A, Jurell G, Wickman M. No differences in aesthetic outcome or patient satisfaction between anatomically shaped and round expandable implants in bilateral breast reconstructions: a randomized study. *Plast Reconstr Surg*. 2010;126(5):1419-1427.
10. Fitzal F, Krois W, Trischler H, et al. The use of a breast symmetry index for objective evaluation of breast cosmesis. *Breast*. 2007;16(4):429-435.
11. Krois W, Romar AK, Wild T, et al. Objective breast symmetry analysis with the breast analyzing tool (BAT): improved tool for clinical trials. *Breast Cancer Res Treat*. 2017;164(2):421-427.
12. Cardoso MJ, Cardoso J, Amaral N, et al. Turning subjective into objective: the BCCT.core software for evaluation of cosmetic results in breast cancer conservative treatment. *Breast*. 2007;16(5):456-461.
13. Cardoso MJ, Cardoso J, Santos AC, et al. Factors determining esthetic outcome after breast cancer conservative treatment. *Breast J*. 2007;13(2):140-146.
14. Cardoso MJ, Cardoso J, Santos AC, Barros H, Cardoso de Oliveira M. Interobserver agreement and consensus over the esthetic evaluation of conservative treatment for breast cancer. *Breast*. 2006;15(1):52-57.
15. Cardoso MJ, Cardoso JS, Wild T, Krois W, Fitzal F. Comparing two objective methods for the aesthetic evaluation of breast cancer conservative treatment. *Breast Cancer Res Treat*. 2009;116(1):149-152.
16. Immink JM, Putter H, Bartelink H, et al. Long-term cosmetic changes after breast-conserving treatment of patients with stage I-II breast cancer and included in the EORTC 'boost versus no boost' trial. *Ann Oncol*. 2012;23(10):2591-2598.
17. Merie R, Browne L, Cardoso JS, et al. Proposal for a gold standard for cosmetic evaluation after breast conserving therapy: Results from the St George and Wollongong Breast Boost trial. *J Med Imaging Radiat Oncol*. 2017;61(6):819-825.
18. Losken A, Seify H, Denson DD, Paredes AA Jr, Carlson GW. Validating three-dimensional imaging of the breast. *Ann Plast Surg*. 2005;54(5):471-476; discussion 477-478.
19. Tepper OM, Unger JG, Small KH, et al. Mammometrics: the standardization of aesthetic and reconstructive breast surgery. *Plast Reconstr Surg*. 2010;125(1):393-400.
20. Isogai N, Sai K, Kamiishi H, Watatani M, Inui H, Shiozaki H. Quantitative analysis of the reconstructed breast using a 3-dimensional laser light scanner. *Ann Plast Surg*. 2006;56(3):237-242.
21. O'Connell RL, Di Micco R, Khabra K, et al. The potential role of three-dimensional surface imaging as a tool to evaluate aesthetic outcome after Breast Conserving Therapy (BCT). *Breast Cancer Res Treat*. 2017;164(2):385-393.
22. Gallo G, Allegra D, Atani YG, et al. Breast shape parametrization through planar projections. *Lecture Notes in Comput Sci*. 2016;10016:135-146.
23. Allegra D, Milotta FLM, Sinitò D, et al. Description of breast morphology through bag of normals representation. *Lecture Notes in Comput Sci*. 2017;10485:511-521.
24. Catanuto G, Patete P, Spano A, Pennati A, Baroni G, Nava MB. New technologies for the assessment of breast surgical outcomes. *Aesthet Surg J*. 2009;29(6):505-508.
25. Cardoso MJ. Is three better than two? The use of 3D scanners in the assessment of aesthetic results in local breast cancer treatment. *Breast*. 2012;21(3):227-228.
26. Gallo G, Guarnera GC, Milanese F, et al. Parametric representation of human breast shapes. *Medical Measurements and Applications*. 2009:26-30.